

INCREASED SENSIBILITY TO ACUTE ACOUSTIC AND BLAST TRAUMA AMONG PATIENTS WITH ACOUSTIC NEUROMA

MARZENA MIELCZAREK and JUREK OLSZEWSKI

Medical University of Lodz, Łódź, Poland

Department of Otolaryngology, Laryngological Oncology, Audiology and Phoniatics

Abstract

The article shows 2 cases of unusual presentation of acute acoustic trauma and blast injury due to occupational exposure. In the case of both patients the range of impaired frequencies in pure tone audiograms was atypical for this kind of causative factor. Both patients had symmetrical hearing before the accident (which was confirmed by provided results of hearing controls during their employment). A history of noise/blast exposure, the onset of symptoms directly after harmful exposure, symmetrical hearing before the trauma documented with audiograms, directed initial diagnosis towards acoustic/blast trauma, however, of atypical course. Acute acoustic and blast trauma and coexisting acoustic neuroma (AN) contributed to, and mutually modified, the course of sudden hearing loss. In the literature there are some reports pointing to a higher sensitivity to acoustic trauma in the case of patients with AN and, on the other hand, indicating noise as one of the causative factors in AN. *Int J Occup Med Environ Health* 2018;31(3)

Key words:

Acute acoustic trauma, Blast injury, Acoustic neuroma, Occupational exposure, Asymmetrical hearing loss, Sensorineural hearing loss

INTRODUCTION

Noise is a commonly known risk factor for hearing impairment. It is estimated that around 30 million people in the European Union are exposed to noise at levels which are potentially harmful to hearing, mainly in the workplace. Nevertheless, there is a growing tendency for noise exposure in recreational activities. Acute acoustic trauma (AAT) is a sudden sensorineural hearing loss induced by acoustic overstimulation, most frequently due to exposure to intense impulse noise. Acute acoustic trauma is typically characterized by the sudden onset of tinnitus in the affected ear/ears, a sensation of blocked ear

and the sudden onset of unilateral/bilateral hearing loss with a temporary or permanent threshold shift, typically with an audiometric notch at 4 kHz or 6 kHz. The 2 main mechanisms which account for hearing loss after AAT are: direct mechanical trauma to the organ of Corti, and metabolic damage following mechanical trauma-dependent processes, resulting in the overproduction of free radicals and lipid peroxidation products.

Less common types of ear trauma are these caused by blast injury. Since ear is the most sensitive pressure transducer, this organ is the one most frequently affected by blast injury. This kind of injury involves mainly tympanic

Received: November 12, 2016. Accepted: July 24, 2017.

Corresponding author: M. Mielczarek, Medical University of Lodz, Department of Otolaryngology, Laryngological Oncology, Audiology and Phoniatics, Żeromskiego 113, 90-549 Łódź, Poland (e-mail: marzena.mielczarek@umed.lodz.pl).

membrane, middle ear and inner ear impairment, less commonly involving external ear [1]. Thus the nature of the hearing loss, as a consequence of above traumas, will depend on structures involved in the process. Acoustic blast injury most commonly results in sensorineural hearing loss. The audiometric configuration of the hearing threshold is a high frequency hearing loss at one or more frequencies, but some may be the case with flat configuration. Although AAT is typically the case with 4 kHz acoustic notch, blast injury results in a sloping high frequency impairment [2].

Most examples of hearing loss amongst adults are bilateral and symmetrical. When unilateral or asymmetrical sensorineural hearing loss is detected, further audiological diagnostics are needed. The most important causes of asymmetrical sensorineural hearing loss are neoplastic lesions in the internal acoustic meatus, such as vestibular schwannomas or other cerebellopontine angle tumors, as well as multiple sclerosis, stroke and other non-neoplastic causes.

Acoustic neuroma (AN) is a benign tumor arising from the perineural Schwann cells of the vestibular branch of the vestibulo-cochlear nerve. The structure of the acoustic nerve is such that high frequency fibers, representing the basal turn of the cochlea, are located peripherally and low frequency fibers, representing the apical turn, are located in the nerve core [3]. Therefore in early stages, schwannoma will typically damage the outer layers of the nerve trunk, resulting in high frequency sensorineural hearing loss.

Acoustic neuroma is one of the risk factors of sudden sensorineural hearing loss (SSHL) (3–15%). Hearing loss tends to be more severe in such cases and is less likely to recover when compared to idiopathic SSHL. Possible mechanisms of hearing loss include a rapid expansion of the tumor due to hemorrhage, edema or cyst formation, or compression of the internal auditory artery by the tumor in the internal auditory canal. Typically, AN is suspected among patients

with asymmetrical hearing loss accompanied by unilateral tinnitus, a low speech discrimination score (SDS) which is disproportional to pure tone audiometry, and abnormal auditory brainstem responses (ABR). However, the value of ABR is currently questioned, as it has been found to have low sensitivity and specificity: the sensitivity being around 58% when tumor size is smaller than 1 cm [4,5]. Currently, the gold standard in imaging diagnostics of asymmetrical sensorineural hearing loss is magnetic resonance imaging (MRI) with gadolinium, which is still frequently indicated by pathological results of ABR.

The article presents a course of noise and blast induced hearing impairment recognized in pure tone audiometry, however, with the involvement of nonspecific for acoustic trauma frequencies. The aim of this report is to point to the fact of increased sensitivity of auditory system in the case of patients with acoustic neuroma.

In the literature there are some reports pointing to a higher sensitivity to acoustic trauma in the case of patients with AN and, on the other hand, indicating noise as one of the causative factors in AN.

MATERIAL AND METHODS

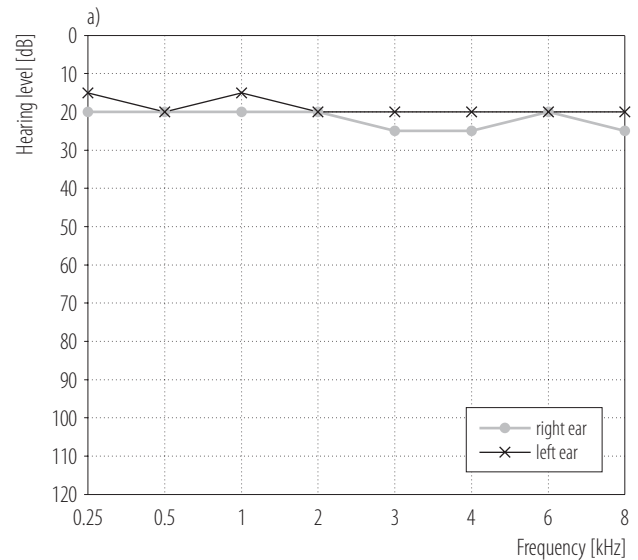
The Patient One, a 31-year-old female, was admitted to the clinic in September 2008 due to acute acoustic trauma after sudden loudspeaker feedback. The patient had been working as a concert sound engineer for 2 years, and her hearing had been screened once a year. The 2 pure tone audiograms prior to the acute acoustic trauma, showed normal, symmetrical hearing bilaterally. Upon admission, the patient reported standing about 1.5 m from the loudspeaker, turned slightly to the left, so the right ear was more exposed to the noise. Directly after the incident, she developed a sensation of hearing loss in the right ear, as well as right-sided tinnitus (a high-pitched sound). The patient reported neither vertigo nor balance disorders. Ear, nose and throat (ENT) examination revealed a normal clinical picture with normal bilateral otoscopy.

Facial motor and sensory function were intact and symmetrical. The patient had no tinnitus before the acoustic trauma incident. A pure tone audiogram in the right ear revealed sensorineural hearing loss with an audiometric notch for 3 kHz. The opposite ear was found to have normal hearing with a notch of 10 dB only for 6 kHz (Figure 1).

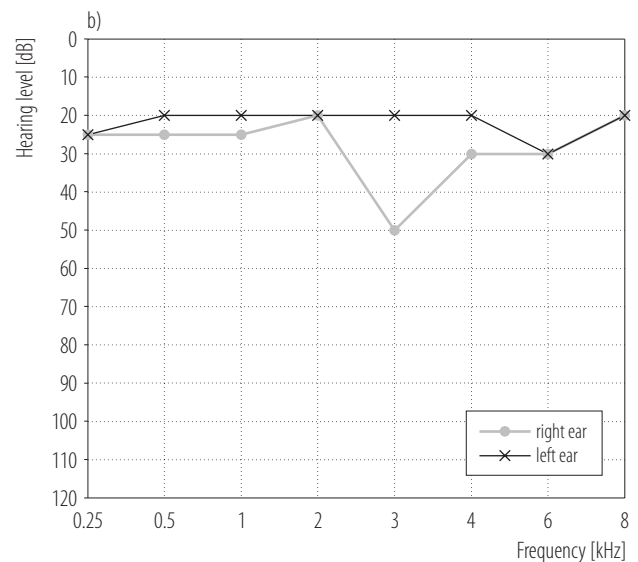
The short increment sensitivity index (SISI) for 3 kHz was 100%, the tone decay test (TDT) was 10 dB. Right-sided tinnitus matched to the contralateral ear: 8 kHz at 15 dB (pure tone sound). Speech audiometry showed a 100% speech discrimination score at 50 dB sound pressure level (SPL) in the right ear, and 100% at 40 dB SPL in the left ear. Impedance audiometry showed a tympanogram type A bilaterally, with a stapedial reflex (SR) threshold of 95 dB (only in the case of 0.5 kHz, 1 kHz) in the right ear and 85 dB in the left ear (in the case of 0.5 kHz, 1 kHz, 2 kHz, 4 kHz).

At this early stage, the patient was diagnosed with right-sided acute acoustic trauma and received pharmacological treatment comprising Methylprednisolone, Piracetamum and Vinpocetinum intravenously. Significant hearing improvement was reported after 6 days, with the pure tone audiogram revealing the hearing threshold to be within normal limits. Two weeks later, on a follow-up in the outpatient clinic, the patient underwent pure tone and speech audiometry, click ABR examination. The audiogram showed a bilateral hearing threshold within normal limits, without signs of acoustic trauma. Auditory brainstem responses revealed symmetrical responses (Vth wave latency at 80 dB nHL (normal hearing level): right – 6.06 ms, left – 6 ms, with interaural (I-V) difference 0.12 ms). Due to abnormal course of acoustic trauma, the patient was referred to pontocerebellar angle MRI with gadolinium. The examination revealed a 13×5×5 mm tumor in the right internal acoustic meatus.

The Patient Two, a 60-year-old male, was admitted to the clinic in December 2014 due to blast injury of the



Hearing threshold within normal ranges bilaterally.



Normal hearing threshold with exception of audiometric notch of 10 dB at 6 kHz in the left ear.

Moderate sensorineural hearing loss the right ear – audiometric notch at 3 kHz.

Fig. 1. Pure tone audiogram of the Patient One: a) before acoustic trauma, b) after acoustic trauma

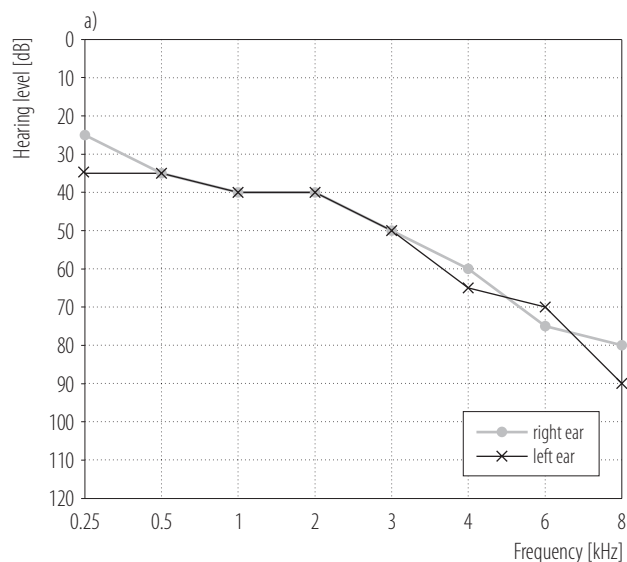
left ear after the sudden explosion of a compressor valve. The patient had been working as a turner for 40 years in a noisy environment, using hearing protectors and having his hearing screened once a year. Before this trauma,

consecutive pure tone audiograms had revealed slowly progressive sensorineural downsloping hearing loss without signs of acoustic trauma. Upon admission, the patient reported that at the time of the explosion, he was squatting about 0.5 m from the compressor valve, with the left side of his head directly exposed to the explosion. Immediately following the incident, the patient experienced a sensation of a blocked left ear, left-sided tinnitus (crackling-like sounds) and skin numbness in the left temporal region. The patient did not report any vertigo or balance disorders before or after the trauma. Ear, nose and throat examination revealed a normal clinical picture with normal otoscopy bilaterally. Facial motor and sensory function were intact and symmetrical.

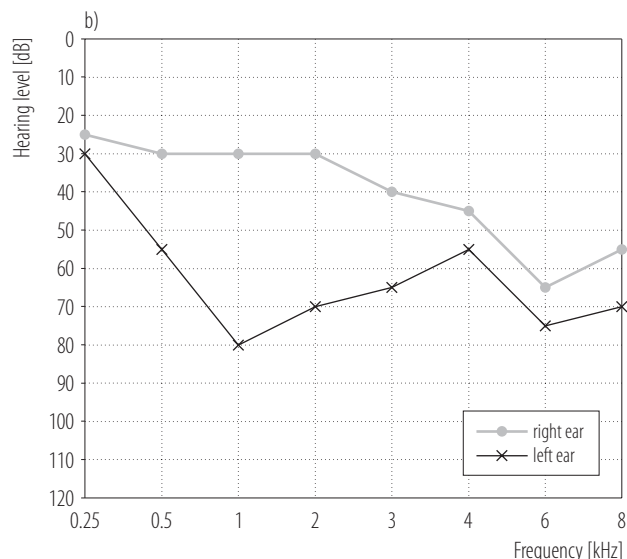
The pure tone audiometry performed in the left ear revealed severe sensorineural hearing loss in frequencies above 0.5 kHz, with audiometrical notches at 1 kHz and 6 kHz. In the right ear, a downsloping hearing threshold was observed with a notch for 6 kHz (Figure 2).

Left-sided tinnitus matched to the contralateral ear: 8 kHz noise at 60 dB. Short increment sensitivity index for 1 kHz and 4 kHz was 100%, TDT test was 10 dB, indicating the presence of a cochlear lesion in the left ear. Speech audiometry in the left ear showed rollover phenomena, speech reception threshold (SRT) at 65 dB SPL and speech recognition score (SRS) 70%. Impedance audiometry showed tympanogram type A bilaterally and no SR bilaterally for ipsilateral or contralateral stimulation.

At this early stage, the patient was diagnosed with left-ear blast injury and received intravenous pharmacological treatment comprising Methylprednisolonum, Piracetamum, Vinpocetinum and Betahistine. No significant hearing improvement was observed after 5 days. Ten days later, on a follow-up in an outpatient clinic, the patient underwent pure tone and speech audiometry, click ABR and videonystagmography (VNG). The pure tone audiogram showed a slight further increase in hearing loss in the left ear. Auditory brainstem responses revealed patho-



Bilateral, symmetrical downsloping sensorineural hearing loss typical for presbycusis.



Bilateral, asymmetrical sensorineural hearing loss. Bilaterally audiometric notch at 6 kHz – a sign of acute acoustic trauma. In the left ear wide audiometric notch appeared with a maximum at 1 kHz.

Fig. 2. Pure tone audiogram of the Patient Two: a) before blast injury, b) after blast injury

logical prolongation of the V wave latency: 6.40 ms in the left ear and 5.80 ms in the right ear at 80 dB nHL, with a 0.4 ms difference in I-V interweave latency. Videonys-

tagmography revealed mixed balance system impairment with a compensated left peripheral lesion. The patient was referred to pontocerebellar angle MRI with gadolinium, which revealed the presence of a 10×4×5 mm tumor in the left internal acoustic meatus.

DISCUSSION

Noise leads to a combination of physiological and anatomical changes within the central auditory pathway as well as mechanical and metabolic damage in the cochlea [6]. It mainly affects the organ of Corti (outer hair cells, supporting cells), the limbus, spiral ligament and vascular stria, as well as the afferent neurons of the auditory nerve and spiral ganglion cells. Acoustic trauma manifests clinically as sensorineural hearing loss of cochlear origin, often accompanied by tinnitus. In human cochlea, the region most susceptible to noise damage is the area around 9–10 mm from the oval window, where 4 kHz frequencies are identified [7].

These cochlear properties result in the presence of an audiometrical notch at 4 kHz, indicating maximal hearing damage at that frequency. In fact, a well-established clinical sign of noise-induced hearing loss in pure tone audiometry is the presence of a temporary or permanent threshold shift, with the notch at 4 kHz. There are 3 possible explanations for the existence of the audiometrical notch.

Firstly, there may be impaired blood supply and greater tendency for impairment of the supporting structures of the hair cells in the cochlear region between 3–6 kHz. Secondly, the primary force of the stapes footplate is orientated towards those hair cells, causing their failure due to permanent hydromechanical action. Finally, since all sound spectra are enhanced at 3 kHz by the external ear canal resonance, and since noise exposure has its maximal effect of one-half octave above the peak frequency of the noise, the greatest hearing loss will be in the 4–6 kHz region [8–11]. Such characteristic audiometric features of noise-induced hearing loss make it relatively easy to recognize.

However, some studies indicate that audiometric notches may not be attributed to any noise exposure [12]. Since noise exposure typically occurs in a free sound field, both ears are expected to be equally affected. Consequently, acute acoustic trauma usually results in symmetrical hearing loss. Nonetheless, some studies indicate that asymmetrical impairment is also possible, for example, among subjects performing arts. On the other hand, there are reports suggesting that the patients with asymmetrical AAT should be screened for AN [13]. Berg et al. give possible explanations for asymmetry in acoustic trauma: an environmental explanation, known as head shadowing, and physiological explanations, such as when men have a greater susceptibility to noise-induced hearing loss (NIHL) than women, in the left ear more than in the right ear [14].

In the presented cases, both explanations could be considered. During acoustic trauma, the patients were standing sideways to the source of the noise. Although the ear directly exposed to noise was more affected, the range of impaired frequencies differed between ears. In the case of the Patient Two, hearing loss was affected more severely and permanently, while the degree of hearing impairment in the Patient One was lower, with complete recovery after pharmacological treatment. Such differences might be attributed to age (greater hearing impairment with advancing age), sex (male sex more predisposed to NIHL), the source of the damaging noise or the size of any tumor [15–17]. Alternatively, according to Nordmann et al., the susceptibility to NIHL depends on recovery or repair processes in the cochlea, rather than the degree of the initial threshold shift [18].

In the case of presented patients, although the notched audiograms at first indicated acoustic trauma, the localization and extent (in the Patient Two) of the acoustic notches was atypical. Similarly, although 100% result in the SISI test indicated the presence of a cochlear lesion, Metz symptoms were not observed in impedance audiometry. Suzuki et al. demonstrated that patients with SSHL had

the highest risk of AN in the case of non-improving or progressive hearing loss with basin-shaped audiograms [19]. The consequence of auditory system blast exposure is peripheral and central damage. Subjecting the brain to primary, secondary and tertiary blast injury results in stretching or shearing of neural projections in the auditory pathway, contusions to the brain surface, blood vessels and inflammatory changes of the soft tissues. Furthermore, the loss of integrity of brainstem nuclei, thalamus and cortex, as well as loss of neural connections throughout central auditory system are possible effects of blast exposure [20]. Barker et al.'s work suggests the fact of higher sensibility to AAT among patients with ipsilateral concomitant AN [13]. According to the authors, cases of asymmetrical noise induced hearing loss should be suspected of coexistence of AN. The direct causative link between AN and AAT has not been established, but the notion that noise exposure and thus mechanical trauma contribute to tumorigenesis has been highlighted.

There is no universally accepted definition of significant pure-tone hearing asymmetry. Saliba et al. propose a 3000 rule in order to reduce the number of negative MRI performed due to autoimmune sensorineural hearing loss (ASHL) [21]. The authors propose an interaural difference of 15 dB or more at 3 kHz as a criterion for hearing impairment conditioned by AN. If the difference is less than 15 dB, a biannual audiometric follow-up is recommended [21]. The Oxford American Handbook of Otolaryngology defines the audiological/otoneurological essentials of acoustic neuroma diagnosis as asymmetric, progressive sensorineural high frequency hearing loss, tinnitus, disequilibrium or vertigo episodes [22].

Although typical hearing loss for AN is retrocochlear, there are cases where a cochlear type of hearing loss occurs. Roosli et al. compared ipsilateral and contralateral histopathological findings in the cochleae of patients with AN [23]. The findings indicate more severe cochlear degeneration on the AN side: greater inner and outer

hair cell loss in the organ of Corti, cochlear neuronal loss, stria vascularis degeneration, higher occurrence of endolymphatic hydrops and an acidophilic-staining precipitate within the inner ear fluid spaces. No correlation was found between tumor volumes and distance of the tumor to the cochlea vs hearing thresholds and speech discrimination scores. The possible mechanisms for the formation of a cochlear lesion in the course of AN are compression of the labyrinthine artery by AN, disturbance in the cytokine balance of the cochlea as a result of cytokine overproduction by the tumor, or concentration of acidophilic (protein) precipitate in the inner ear fluids [23]. Such findings may justify and indicate a cochlear pattern of hearing loss in AN. The usual pattern of audiometric results in the course of AN is asymmetrical or unilateral sensorineural hearing loss, affecting mainly high to mild frequencies, unilateral tinnitus and balance disorders.

The literature, however, demonstrates that every type or shape of audiogram, including normal hearing is possible in the course of AN. Hearing impairment at high and medium frequencies results from the anatomical structure of the cochlear nerve: mid- and high-frequency nerve fibers lie on the outer portion. However, middle to low frequency hearing loss may be explained by the position of middle to low frequency fibers closer to some portions of the superior and inferior vestibular nerves [24]. On the other hand, the presence of a large purely cisternal vestibular schwannoma may be audiometrically asymptomatic for extended periods of time. Tutar et al. do not note any correlation between tumor size and hearing levels at each frequency among AN patients [25].

Hearing loss in the course of AN is therefore probably due to a combination of 2 mechanisms: cochlear, as described above, and retrocochlear, i.e., compression of the cochlear nerve by the growing tumor and ischemia caused by pressure of the cochlear blood supply [26]. The atrophy of the cochlear nerve results in a discrepancy between speech discrimination scores and pure tone hearing thresholds,

which is considered one of the most significant and differential feature of AN. Studies have shown that significant shifts in speech discrimination score may be attributed to a loss of more than 80% of cochlear neurons [27,28]. Both, initial peripheral and central auditory pathway damage, appear to be a reason for higher sensitivity of auditory structures to AAT.

In the case of the Patient One, a young woman, the audiometric picture could indicate cochlear origin of hearing loss: i.e., the presence of an audiometric notch at a single frequency, a complete recovery to normal hearing, normal ABRs and mildly affected speech discrimination. The 3 kHz notch could be a result of modified cochlear micromechanics due to changes in the hair cells and inner ear fluids. The improvement in hearing after pharmacological treatment indicates that the noise was the source of hearing impairment with sufficient repair processes within the cochlea. On the contrary, lack of most stapedial reflexes has been a sign of retrocochlear lesion. The speech audiometry (SRT vs. pure tone average 0.5 kHz, 1 kHz, 2 kHz \pm 12 dB) in the case of the Patient One was hardly disproportional to the average pure tone whereas a rollover phenomenon was found in the case of the Patient Two, with a rollover index 0.42 [29,30].

Before AAT and blast injury, neither of the patients had complained of vertigo or disequilibrium, not in the past or at the time of interview. Compensatory mechanisms influenced by vision and the contralateral vestibular organ, together with the lack of previous acoustic symptoms, may have possibly contributed to the delay in diagnosis.

Preston-Martin et al. support the hypothesis that noise and mechanical trauma contribute to tumorigenesis [31]. The possible explanation considers cell proliferation occurring during repair process. The DNA copying errors resulting in chromosomal changes are causative factors for neoplastic transformation. The more cell divisions (so more repair processes) the more probability that mutation occurs. On the other hand the authors hypothesize

that the ignition site of AN may be by exposure to a carcinogen (such as ionizing radiation) and following exposure to noise (acoustic trauma) will promote the pathological process since increases cell proliferation [32,33]. Albanes and Winick showed that cancer risk was proportional to a number of proliferating cells that occurred during repair process [34]. Many studies have shown that acoustic trauma from impulse noise causes mechanical damage of the acoustic nerve and surrounding tissues. Furthermore, the electrolytes disequilibrium of cochlea fluids and free radicals appearing after noise overstimulation may induce cochlear DNA impairment [33,35].

In our research on both patients AN appeared to be a factor increasing (modifying) sensibility of auditory system to hearing impairment. However, in the case of the Patient Two, we cannot exclude probability that noise could have been a causative factor for AN.

CONCLUSIONS

The article presents cases of acute acoustic and blast trauma due to occupational exposure. The course of the disease was conditioned by multifactorial etiology. Although clinical picture was typical for acute acoustic trauma, audiometrical results were not specific for either acoustic/blast trauma or acoustic neuroma. Acute acoustic trauma, coexisting AN and presbycusis apparently contributed to and mutually modified the course of hearing loss. In the literature, there are reports describing higher sensibility to AAT among patients with acoustic neuroma, likewise, there are studies on asymmetrical hearing impairment resulting from AAT.

The history of noise/blast exposure, the onset of symptoms directly after noise/blast exposure, symmetrical hearing before acoustic trauma documented with audiograms directed initial diagnosis towards AAT, however, of an atypical course. The following audiological diagnostics indicated a discrepancy between outcomes which were expected in AAT and those which were obtained. Atypical course of acute acoustic and blast trauma indicated additional factor

influencing the course of the disease. Thus, we support Baker et al.'s [13] concept about radiological imaging (MRI) in cases of asymmetrical noise-induced hearing loss.

REFERENCES

1. Garth RJN. Blast injury of the ear: An overview and guide to management. *Injury*. 1995;26(6):363–6, [https://doi.org/10.1016/0020-1383\(95\)00042-8](https://doi.org/10.1016/0020-1383(95)00042-8).
2. Fausti SA, Wilmington DJ, Gallun FJ, Myers PJ, Henry JA. Auditory and vestibular dysfunction associated with blast-related traumatic brain injury. *J Rehabil Res Dev*. 2009;46(6):797–810, <https://doi.org/10.1682/JRRD.2008.09.0118>.
3. Sando I. The anatomical interrelationships of the cochlear nerve fibers. *Acta Otolaryngol*. 1965;59:417–36, <https://doi.org/10.3109/00016486509124577>.
4. Cueva RA. Auditory brainstem response versus magnetic resonance imaging for the evaluation of asymmetric sensorineural hearing loss. *Laryngoscope*. 2004;114(10):1686–92, <https://doi.org/10.1097/00005537-200410000-00003>.
5. Schmidt RJ, Sataloff RT, Newman J, Spiegel JR, Myers DL. The sensitivity of auditory brainstem response testing for the diagnosis of acoustic neuromas. *Arch Otolaryngol Head Neck Surg*. 2001;127(1):19–22, <https://doi.org/10.1001/archotol.127.1.19>.
6. Basta D, Tzschentke B, Ernst A. Noise-induced cell death in the mouse medial geniculate body and primary auditory cortex. *Neurosci Lett*. 2005;381(1–2):199–204, <https://doi.org/10.1016/j.neulet.2005.02.034>.
7. Hilding AC. Studies on the otic labyrinth. Anatomic explanation for the hearing dip at 4096 characteristic of acoustic trauma and presbycusis. *Ann Otol Rhinol Laryngol*. 1953;62(4):950–6, <https://doi.org/10.1177/000348945306200402>.
8. Crowe SJ, Guild SR, Polvogt LM. Observations on the pathology of high-tone deafness. *Johns Hopkins Med J*. 1934;54:315–8.
9. Bohne BA. Safe level for noise exposure? *Ann Otol Rhinol Laryngol*. 1976;85:711–24, <https://doi.org/10.1177/000348947608500602>.
10. Pierson LL, Gerhardt KJ, Rodriguez GP, Yanke RB. Relationship between outer ear resonance and permanent noise-induced hearing loss. *Am J Otolaryngol*. 1994;15(1):37–40, [https://doi.org/10.1016/0196-0709\(94\)90038-8](https://doi.org/10.1016/0196-0709(94)90038-8).
11. Ward WD. Noise induced hearing damage. In: Paparella MM, Shumrick DA, Gluckman JL, Meyerhoff WL, editors. *Otolaryngology*. 2nd ed. Philadelphia: W.B. Saunders Company; 1991. p. 1639–52.
12. Osei-Lah V, Yeoh LH. High frequency audiometric notch: An outpatient clinic survey. *Int J Audiol*. 2010;49(2):95–8, <https://doi.org/10.3109/14992020903300423>.
13. Baker R, Stevens-King A, Bhat N, Leong P. Should patients with asymmetrical noise-induced hearing loss be screened for vestibular schwannomas? *Clin Otolaryngol Allied Sci*. 2003;28(4):346–51, <https://doi.org/10.1046/j.1365-2273.2003.00721.x>.
14. Berg RL, Pickett W, Linneman JG, Wood DJ, Marlenga B. Asymmetry in noise-induced hearing loss: Evaluation of two competing theories. *Noise Health*. 2014;16:102–7, <https://doi.org/10.4103/1463-1741.132092>.
15. Strauss S, Swanepoel DW, Becker P, Eloff Z, Hall JW III. Noise and age-related hearing loss: A study of 40 123 gold miners in South Africa. *Int J Audiol*. 2014;53(Suppl 2):S66–75, <https://doi.org/10.3109/14992027.2013.865846>.
16. Henderson D, Subramaniam M, Boettcher FA. Individual susceptibility to noise-induced hearing loss: An old topic revisited. *Ear Hear*. 1993;14(3):152–68, <https://doi.org/10.1097/00003446-199306000-00002>.
17. Harun A, Agrawal Y, Tan M, Niparko JK, Francis HW. Sex and age associations with vestibular schwannoma size and presenting symptoms. *Otol Neurotol*. 2012;33(9):1604–10, <https://doi.org/10.1097/MAO.0b013e31826dba9e>.
18. Nordmann AS, Bohne BA, Harding GW. Histopathological differences between temporary and permanent threshold shift. *Hear Res*. 2000;139(1–2):13–30, [https://doi.org/10.1016/S0378-5955\(99\)00163-X](https://doi.org/10.1016/S0378-5955(99)00163-X).
19. Suzuki M, Hashimoto S, Kano S, Okitsu T. Prevalence of acoustic neuroma associated with each configuration of pure

- tone audiogram in patients with asymmetric sensorineural hearing loss. *Ann Otol Rhinol Laryngol* 2010;119(9):615–8, <https://doi.org/10.1177/000348941011900908>.
20. Gallun FJ, Lewis MS, Folmer RL, Diedesch AC, Kubli LR, McDermott DJ, et al. Implications of blast exposure for central auditory function: A review. *J Rehabil Res Dev*. 2012; 49(7):1059–74, <https://doi.org/10.1682/JRRD.2010.09.0166>.
 21. Saliba I, Martineau G, Chagnon M. Asymmetric hearing loss: Rule 3,000 for screening vestibular schwannoma. *Otol Neurotol*. 2009;30(4):515–21, <https://doi.org/10.1097/MAO.0b013e3181a5297a>.
 22. Blitzer A, Song P, Schwartz J. *Oxford American Handbook of Otolaryngology*. Oxford University Press, USA. 2008.
 23. Roosli C, Linthicum FH Jr, Cureoglu S, Merchant SN. Dysfunction of the cochlea contributing to hearing loss in acoustic neuromas: An underappreciated entity. *Otol Neurotol* 2012;33(3):473–80, <https://doi.org/10.1097/MAO.0b013e318248ee02>.
 24. Spoendlin H, Schrott A. Analysis of the human auditory nerve. *Hear Res*. 1989;43(1):25–38, [https://doi.org/10.1016/0378-5955\(89\)90056-7](https://doi.org/10.1016/0378-5955(89)90056-7).
 25. Tutar H, Duzlu M, Göksu N, Ustün S, Bayazit Y. Audiological correlates of tumor parameters in acoustic neuromas. *Eur Arch Otorhinolaryngol*. 2013;270(2):437–41, <https://doi.org/10.1007/s00405-012-1954-2>.
 26. Prasher, D, Tun T, Brookes G, Luxon LM. Mechanisms of hearing loss in acoustic neuroma: An otoacoustic emission study. *Acta Otolaryngol*. 1995(3);115:375–81, <https://doi.org/10.3109/00016489509139332>.
 27. Pauler M, Schuknecht HF, Thornton AR. Correlative studies of cochlear neuronal loss with speech discrimination and pure-tone thresholds. *Arch Otorhinolaryngol*. 1986; 243(3):200–6, <https://doi.org/10.1007/BF00470622>.
 28. Schuknecht HF, Woellner RC. An experimental and clinical study of deafness from lesions of the cochlear nerve. *J Laryngol Otol*. 1955;69(2):75–97, <https://doi.org/10.1017/S0022215100050465>.
 29. Gelfand SA. *Essentials of audiology*. 3rd ed. New York: Thieme; 2009. p. 239–73.
 30. Carhart R, Porter LS. Audiometric configuration and prediction of threshold for spondees. *J Speech Hear Res*. 1971;14(3):486–95, <https://doi.org/10.1044/jshr.1403.486>.
 31. Preston-Martin S, Thomas DC, Wright WE, Henderson BE. Noise trauma in the aetiology of acoustic neuromas in men in Los Angeles County, 1978–1985. *Br J Cancer*. 1989;59(5): 783–6, <https://doi.org/10.1038/bjc.1989.163>.
 32. Mantao C, Zuoxu F, Xiuju Z, Fei C, Liang W. Risk factors of acoustic neuroma: Systematic review and meta-analysis. *Yonsei Med J*. 2016;57(3):776–83, <https://doi.org/10.3349/ymj.2016.57.3.776>.
 33. Van Campen LE, Murphy WJ, Franks JR, Mathias PI, Torason MA. Oxidative DNA damage is associated with intense noise exposure in the rat. *Hear Res*. 2002;164(1–2):29–38, [https://doi.org/10.1016/S0378-5955\(01\)00391-4](https://doi.org/10.1016/S0378-5955(01)00391-4).
 34. Albanes D, Winick M. Are cell number and cell proliferation risk factors for cancer? *J Natl Cancer Inst*. 1988;80(10): 772–4, <https://doi.org/10.1093/jnci/80.10.772>.
 35. Hours M, Bernard M, Arslan M, Montestrucq L, Richardson L, Deltour I, et al. Can loud noise cause acoustic neuroma? Analysis of the INTERPHONE study in France. *Occup Environ Med*. 2009;66(7):480–6, <https://doi.org/10.1136/oem.2008.042101>.