

# TAKOTSUBO CARDIOMYOPATHY IN THE CASE OF 72-YEAR-OLD TEACHER AFTER WORK-RELATED PSYCHOLOGICAL STRESS. EVOLUTION OF LEFT VENTRICULAR LONGITUDINAL STRAIN – DELAYED BUT COMPLETE RECOVERY IN AUTOMATED FUNCTION IMAGING (AFI)

KARINA WIERZBOWSKA-DRABIK<sup>1</sup>, ANDRZEJ MARCINKIEWICZ<sup>2</sup>, PIOTR HAMALA<sup>1</sup>,  
EWA TRZOS<sup>1</sup>, PIOTR LIPIEC<sup>1</sup>, MAŁGORZATA KURPESA<sup>1</sup>, RADOSŁAW KRĘCKI<sup>1</sup>,  
MICHAŁ PLEWKA<sup>1</sup>, and JAROSŁAW DAMIAN KASPRZAK<sup>1</sup>

<sup>1</sup> Medical University of Lodz, Łódź, Poland

Chair and Department of Cardiology

<sup>2</sup> Nofer Institute of Occupational Medicine, Łódź, Poland

Department of Occupational Diseases and Environmental Health, Health Policy Unit

## Abstract

Takotsubo cardiomyopathy (TC) is related to a transient systolic dysfunction of left ventricle (LV), accompanied by clinical and electrocardiographic symptoms of myocardial ischemia in the absence of hemodynamically significant coronary artery disease. Takotsubo cardiomyopathy is usually provoked by a psychologically or/and physically stressful event which may be related to occupational activities. Although visually assessed evolution of LV function is well documented, the data concerning strain changes is sparse and various patterns of deformation abnormalities are suggested. We have described a 72-year-old woman with chest pain related to a lecture given at the meeting of the Senior University, fulfilling all the Mayo Clinic criteria of the TC. The longitudinal strain analysis with automated function imaging (AFI) documented severe impairment and stepwise recovery of regional and global LV contractility. The case described confirms that accurate diagnosis, treatment and documenting of functional improvement in takotsubo cardiomyopathy may enable the return to occupational activities even for elderly persons. *Int J Occup Med Environ Health* 2017;30(4):681–683

## Key words:

Professional activity, Occupational stress, Transthoracic echocardiography, Takotsubo cardiomyopathy, Longitudinal strain, AFI analysis

Received: February 17, 2016. Accepted: July 7, 2016.

Corresponding author: K. Wierzbowska-Drabik, Medical University of Lodz, Chair and Department of Cardiology, Kniaziewiczza 1/5, 91-347 Łódź, Poland (e-mail: [wierzbowska@ptkardio.pl](mailto:wierzbowska@ptkardio.pl)).

## CASE DESCRIPTION

The 72-year-old woman, still professionally active as a lecturer at the Senior University, was admitted to the Cardiology Department because of resting retrosternal and epigastric (classified as IV class of the Canadian Cardiovascular Society (CCS)) pain with nausea. The onset of symptoms was associated with strong stage-fright related to the lecture given a few hours ago, and a former history of angina and heart failure symptoms during daily activity were negative. The medical history revealed hypertension and hypothyroidisms and baseline electrocardiogram ST segment elevation in V2–V6 leads with negative T wave in aVL lead. Laboratory analyses confirmed moderate increase in troponin to 0.711 ng/ml (normal values < 0.1 ng/ml) and kinase levels – to 29.77 ng/ml (normal range 0–3.77 ng/ml) as well as mild hypercholesterolemia and mildly increased N-terminal prohormone of brain natriuretic peptide (NT-pro BNP) level 377 pg/ml.

During baseline transthoracic echocardiography (TTE), widened distal part of left ventricle (LV) with dyskinesia and hyperkinesia of basal segments and LV ejection fraction calculated from 3D data sets of 30% was observed. The peak systolic longitudinal strain analysis with automated function imaging (AFI) revealed severe reduction of strain absolute values in apical part (mean strain value of 1%) and moderate impairment in middle LV (mean absolute value for medial segments 11.2%) (Photo 1a–c). The angiography demonstrated the lack of coronary stenoses, and medical treatment including acetylsalicylic acid (ASA), clopidogrel, nitroglycerin, bisoprolol and atorvastatin was recommended.

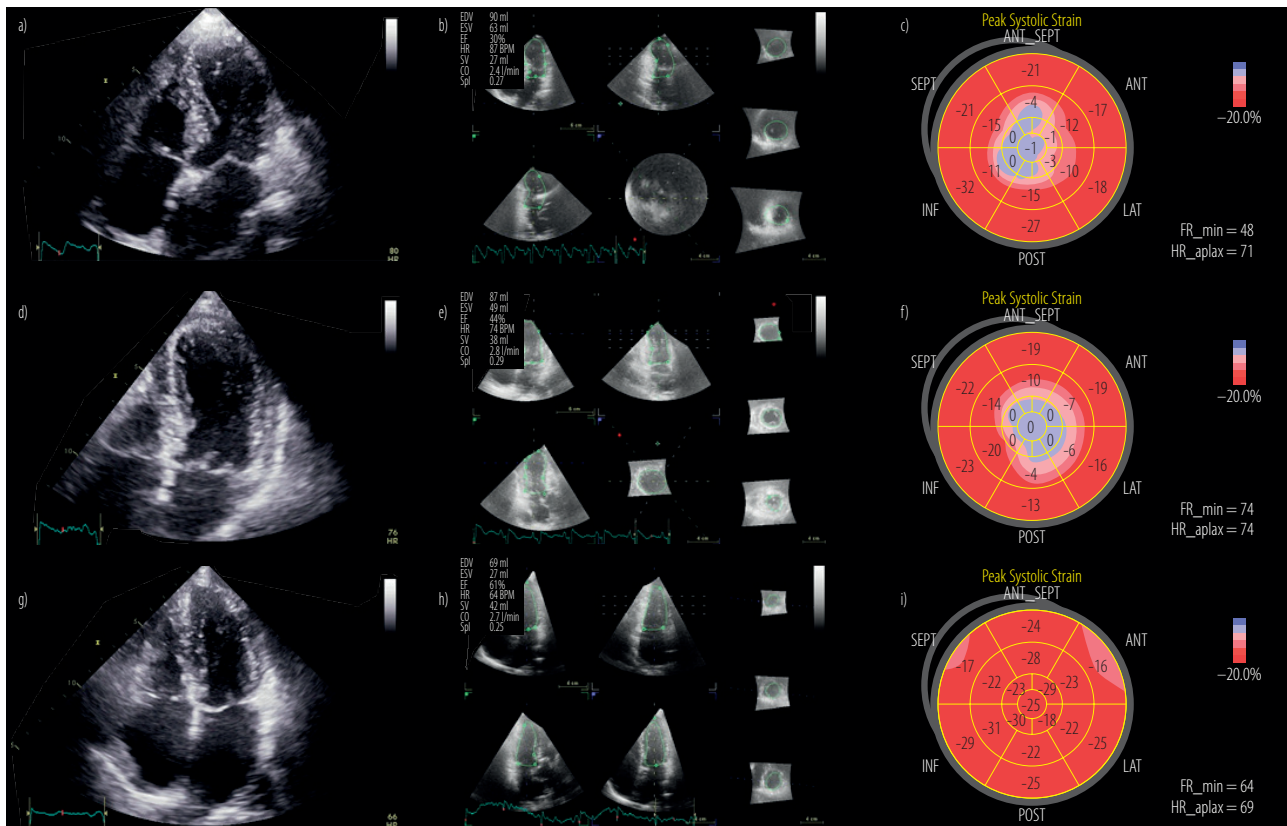
After four days, in spite of improvement of visually assessed regional contractility and ejection fraction, the AFI did not show any increase in the strain in apical (complete lack of deformation) and mid part of LV (mean value of strain 10.2%) (Photo 1d–f). On the contrary, after 4 months regional and global contractility completely recovered in both visual and quantitative assessment, ejection fraction

reached 61% and global absolute strain was 24.1% (Photo 1g–i). After this time the patient was asymptomatic according to angina and remained I class according to the New York Heart Association (NYHA). Our case documents the quantitatively delayed but full recovery of severely impaired regional LV function in takotsubo cardiomyopathy (TC), which had started later than the visual and ejection fraction betterment [1–3].

Since the lack of significant coronary artery stenoses and because of heart function recovery, the patient, despite advanced age, was allowed to return to the professional activity. It seems that the quantitative analysis of LV function with the AFI may provide objective documentation of complete heart function recovery, or on the contrary, may precisely describe the loss of myocardial function which may have the particular significance in occupational medicine [4].

## REFERENCES

1. Kumar S, Mostow N, Grimm RA. Quick resolution of takotsubo cardiomyopathy: A brief review. *Echocardiography*. 2008;25(10):1117–20, <https://doi.org/10.1111/j.1540-8175.2008.00775.x>.
2. Mielczarek A, Kasprzak JD, Marcinkiewicz A, Kurpesa M, Uznańska-Loch B, Wierzbowska-Drabik K. Broken heart as work-related accident: Occupational stress as a cause of takotsubo cardiomyopathy in 55-year-old female teacher – Role of automated function imaging in diagnostic workflow. *Int J Occup Med Environ Health*. 2015;28(6):1031–4, <https://doi.org/10.13075/ijomeh.1896.00564>.
3. Abudiab MM, Wilansky S, Lester SJ, Yousefzai R, Tyler R, Tajik AJ. Transient apical thickening following apical ballooning syndrome: A case series. *Echocardiography*. 2015;32(11):1723–7, <https://doi.org/10.1111/echo.13001>.
4. Neil CJ, Nguyen TH, Singh K, Raman B, Stansborough J, Dawson D, et al. Relation of delayed recovery of myocardial function after takotsubo cardiomyopathy to subsequent quality of life. *Am J Cardiol*. 2015;115(8):1085–9, <https://doi.org/10.1016/j.amjcard.2015.01.541>.



EDV – end-diastolic volume; ESV – end-systolic volume; EF – ejection fraction; HR – heart rate; SV – stroke volume; CO – cardiac output; SpI – sphericity index.

Upper panel: The baseline transthoracic echocardiography (TTE) examination revealing:

- Apical dyskinesia – systolic frame of 4-chamber view.
- LV ejection fraction of 30%.
- Severe impairment of longitudinal strain in apical and mid LV segments. The mean absolute value of systolic longitudinal strain in baseline segments fits in the normal range 22.7% whereas this parameter for mid segments is moderate: 11.2% and for apical segments it severely decreased: 1%.

Mid panel: The TTE study after 4 days. Despite the improvement of LV ejection fraction to 44% the strain analysis did not increase in apical and mid LV segments:

- Apical dyskinesia – systolic frame of 4-chamber view.
- LV ejection fraction of 44%.
- Severe impairment of longitudinal strain in apical and mid LV segments. The mean absolute value of systolic longitudinal strain in baseline segments fits in the normal range – 18.7% whereas this parameter for mid segments still moderately decreased – 10.2% and apical segments showed the lack of deformation.

Lower panel: The TTE study after 4 months. Full recovery of LV systolic function and longitudinal deformation was observed:

- Normokinesis in visual assessment – systolic frame of 4-chamber view.
- LV ejection fraction of 61%.
- Normal values of systolic longitudinal strain in all LV segments. The mean value for baseline segments: 22.7%, for mid segments: 24.7%, for apical: 25%.

**Photo 1.** Evolution of left ventricle (LV) function in the case of the 72-year-old teacher after work-related psychological stress with takotsubo cardiomyopathy (TC)

This work is available in Open Access model and licensed under a Creative Commons Attribution-NonCommercial 3.0 Poland License – <http://creativecommons.org/licenses/by-nc/3.0/pl/deed.en>.